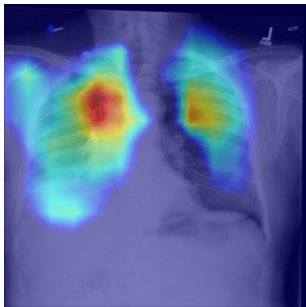
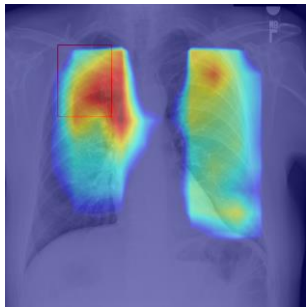


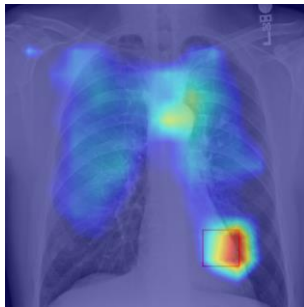
Fracture



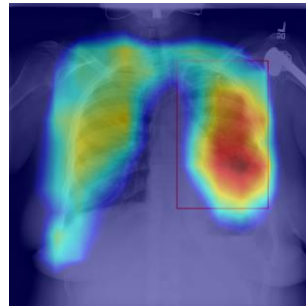
Fibrosis



Mass



Pleural Thickening



Nodule

