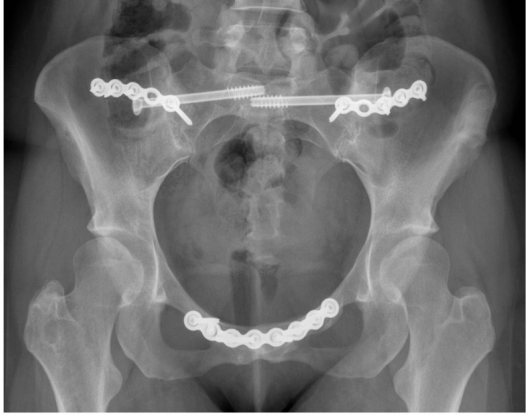


CC BY [Ali et al. (2020)]



Caption: Anteroposterior pelvic radiograph of a 30-year-old female diagnosed with Ehlers-Danlos Syndrome demonstrating fusion of pubic symphysis and both sacroiliac joints (anterior plating, bone grafting and sacroiliac screw insertion)



Manual concept
extraction



C1306645 - Plain x-ray



Caption
pre-processing



Concepts extraction
and linking using
MedCat



Concepts
filtering



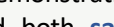
C1305773 - Entire
symphysis pubis



C0301559 - Screw



C1999039 -
Anterior-Posterior



C0555898 - Sacroiliac



C0036036 -
Sacroiliac joint
structure



C1999039 - Diagnosis

C1306645 - Pelvis

Caption: Anteroposterior **pelvic** radiograph of a 30-year-old female **diagnosed** with Ehlers-Danlos Syndrome demonstrating fusion of **pubic symphysis**, and both **sacroiliac joints** (**anterior** plating, bone grafting and **sacroiliac screw** insertion)