

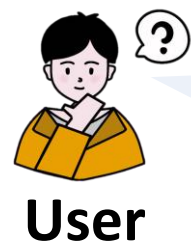


What are the characteristics of ulcerative colitis?

Ulcerative colitis is a chronic inflammatory bowel disease that affects the lining of the colon and rectum. Several characteristics may be observed :

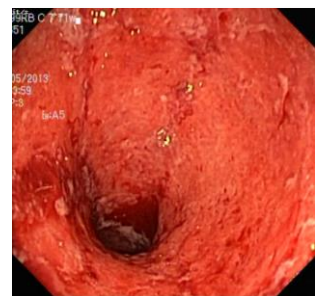- (1) Inflammation, (2) Ulcers, (3) Fissures, (4) Bleeding, (5) Skip lesions.




General Model



Please diagnose this image.




The patient likely has **esophagitis**.

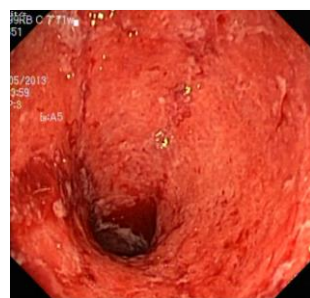

General Model

(a)



You are given an endoscopy image and the diagnose is ulcerative colitis. Please generate a medical report consisting of findings and impression.



Findings: (1) The image presents an endoscopic view of the colon. (2) A deep ulceration located centrally in the image. (3) The surrounding tissue is affected by inflammation, characterized by redness and swelling.

Impression: The patient likely has ulcerative colitis.

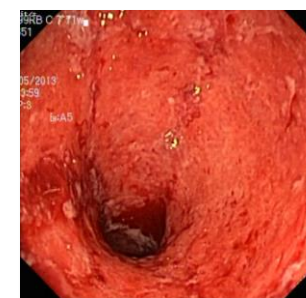

General Model

(b)



You are given a medical image. You need to provide medical report consisting of findings and impression.



Findings:(1) The image shows an endoscopic view of the colon. (2) The colon is inflamed with redness and swelling. (3) There are ulcers and erosions on the colon's surface. (4)The colon's lining is friable and easily damaged.

Impression: The findings are consistent with a diagnosis of **ulcerative colitis**.



MedDr

(c)