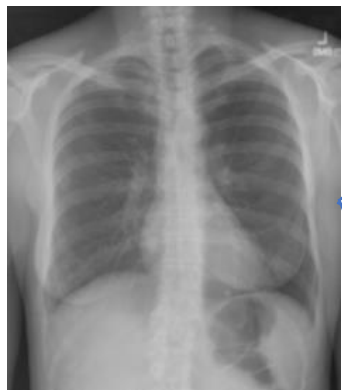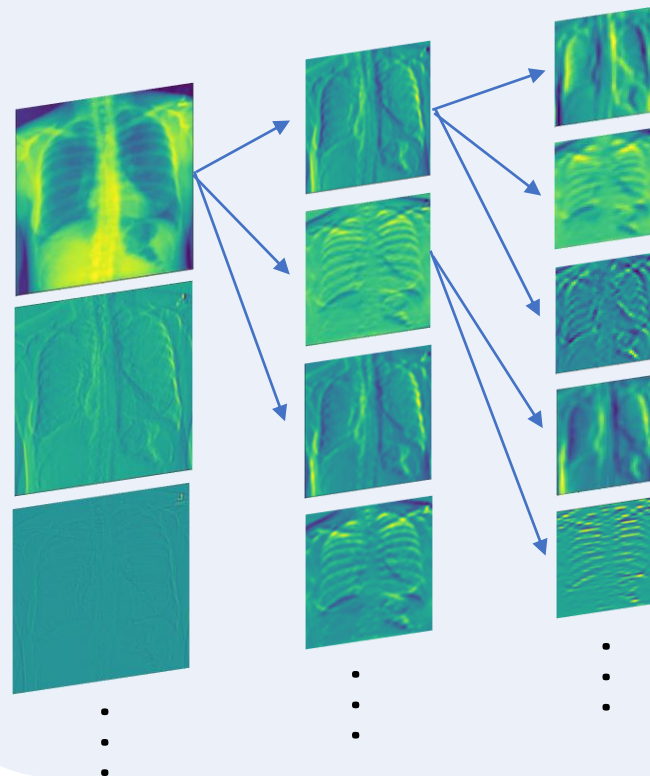


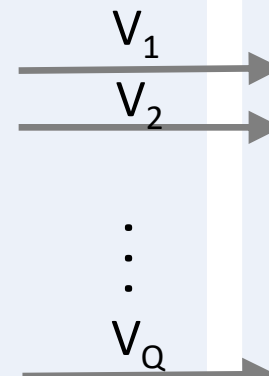
Chest X-Ray Image



PixelHop++ Output Channels



PCA and Concatenation



Transformer

Atelectasis
Effusion
Pneumonia
Nodule
Emphysema
Fibrosis
PT

Text Report

The cardiac and mediastinal contours are within normal limits. The lungs are well-inflated and clear. There is an 8mm nodule in the left lower lobe, XXXX calcified granuloma ...

