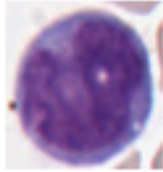
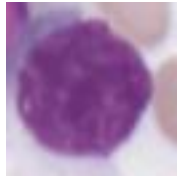




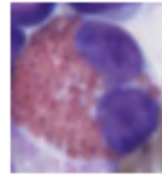
Basophil



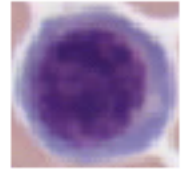
Blast



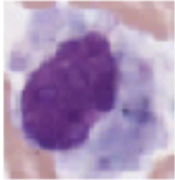
Debris



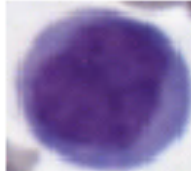
Eosinophil



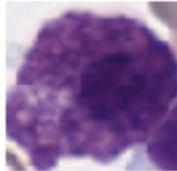
Erythroblast



Histiocyte



Lymphocyte



Mast Cell



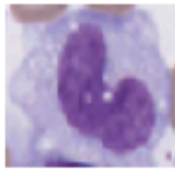
Megakaryocyte



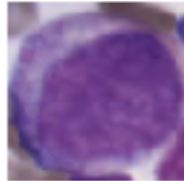
Megakaryocyte  
Nucleus



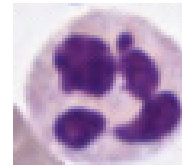
Metamyelocyte



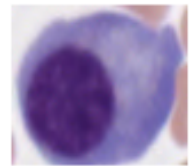
Monocyte



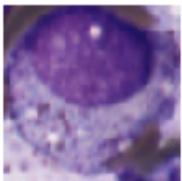
Myelocyte



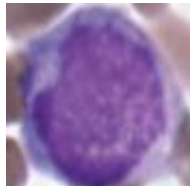
Neutrophil



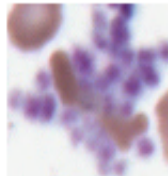
Plasma Cell



Promyelocyte



Other cell



Platelet Clump



Platelet