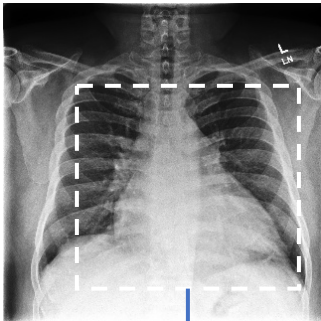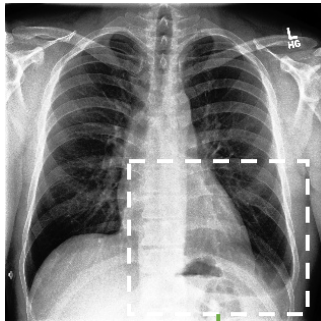


Severe **cardiomegaly**
is noted in the image
with enlarged...



Radiograph shows
pleural effusion in
the right...