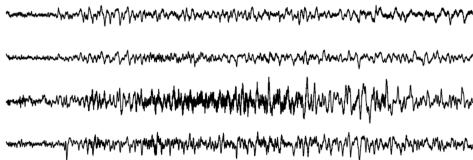


Doctor written Report



Abnormal EEG; awake and drowsy states due to the presence of 1) Generalized theta slowing of the background 2) Intermittent focal delta slowing over the right temporal region. No epileptiform abnormalities or organized electrographic seizures were detected.

CLARA with edit module and defined anchor words

This is an abnormal EEG. Drowsy states were observed. Awake states were seen. Generalized theta slowing of the background was present. Focal delta slowing was seen. Epileptiform abnormalities were not seen. Electrographic seizures were not detected.